Ilmiy tadqiqotlar va ularning yechimlari jurnali
Aoka guvohnoma № 323759 ISSN: 3060-4818

CONGENITAL CURRENTS: DIVERSE ETIOLOGIES OF PEDIATRIC HYDROCEPHALUS IN A RETROSPECTIVE CASE SERIES

Zoha Sheza Fathima

Medical Student , Samarkand state medical university, Uzbekistan,

https://orcid.org/0009-0008-9583-1814,

Babitti Nongrang

Medical Student , Samarkand state medical university , Uzbekistan

Ibapyntngen Shlem

Medical Student Samarkand state medical university, Uzbekistan ,

https://orcid.org/0009-0004-3467-5839

Nisa Akbar

Medical Student, Samarkand state medical university, Uzbekistan

https://orcid.org/0009-0000-9601-0358

Abstract: The information presented in this article has been obtained from the previous medical cases of children with hydrocephalus. The contents in this document explains how hydrocephalus has affected the patients with these cases. The study design as a retrospective or prospective observational study conducted in a pediatric ward diagnosed with hydrocephalus. The study involves study population, data collection, study objective, inclusion criteria and treatment effectiveness. The aim of this study is to analyze the causes, clinical diagnosis, management strategies of the pediatric hydrocephalus and to focus on early detection and treatment.

Key words: Hydrocephalus, Cerebrospinal fluid, aqueductal stenosis, compensated secondary hydrocephalus, occlusive triventricular

Introduction: Pediatric hydrocephalus is a common disorder of the CSF. It is the accumulation or building up of cerebrospinal fluids in the brain at the time of birth or during infancy, childhood, or adolescence. The sign and symptoms varies with age of the individuals.

Methods: All cases were documented between 2018 and 2024. In most of the cases of pediatric hydrocephalus, children are present with a spectrum, or range, of neurological conditions rather than a single proper pattern.

Results: After studying 6-7 cases, a total of 7 pediatric patients (patients A-G) aged 2 months to 6 years, all are being diagnosed with Hydrocephalus. All the information regarding these cases were collected from MRI, CT/MSCT, Tractography, and neurological consultation reports.

Introduction

Paediatric Hydrocephalus is a common disorder of cerebral spinal fluid (CSF). Due to accumulation or buildup of fluid in brain at the time of birth or during infancy, childhood, or adolescence. The signs and symptoms may varies by age but often include the enlargement of head, bulging fontanels (soft spots), irritability, high pitch crying, sunsetting eyes, scalp changes(dilated veins in scalp), seizure, and also apnea(pauses in breathing). [1]

The main causes of pediatric hydrocephalus are congenital malformations, neural tube defects, and central nervous system (CNS) hemorrhage also infection and tumor. The most common causes are aqueduct stenosis, chiari II Malformations and intraventricular hemorrhage .

Pediatric hydrocephalus has two main classification . The first one is based on primary classification which includes congenital hydrocephalus and acquired hydrocephalus. The second is mechanism based classifications which include non- communicating (obstructive) hydrocephalus and the communicating hydrocephalus .[2]

There are numerous test that can help in the diagnosis of pediatric hydrocephalus(in infant and children). First by taking measurements of the size of baby's head, further diagnostic test that include brain imaging techniques such as ultrasonography (us), computed tomography (CT), multi slice computed tomography (MSCT) and magnetic resonance imaging (MRI).

There are several surgical treatments for pediatric hydrocephalus which mainly include the surgical CSF Shunting and utero treatment which is possible via surgical closure of associated neural tube defects. The long term outcome for children with hydrocephalus vary widely depending on intrinsic and extrinsic factors. Advances in genomics, brain imaging and other technologies are beginning to refine the definition of hydrocephalus, increase precision of prognostication and to identify non surgical treatment strategies.

Materials and Methods

Study Design:

This is a retrospective analysis of the data gathered from the Neurosurgery Department of Samarkand State Medical University, explaining 7 distinct case reports. All cases were documented between 2018 and 2024.

In most cases of pediatric hydrocephalus, children present with a spectrum, or range, of neurological conditions rather than a single proper pattern. Clinical presentations do tend to vary, with certain patients demonstrating features such as psychomotor developmental issue, secondary headaches and much more. A portion of cases are considered idiopathic, or sympathetic, while others are attributed to some identifiable underlying causes. However, all cases could not be "definitively" categorized due to limited or inconclusive diagnostic data.

Study Objective:

The principal objective of this analysis was to evaluate the clinical features of pediatric hydrocephalus across various age groups and it's underlying causes. Secondary aim is to examine the

most common etiologies contributing to these conditions and to determine the brain regions most frequently involved, along with the typical sites of onset and progression of ventricular enlargement.

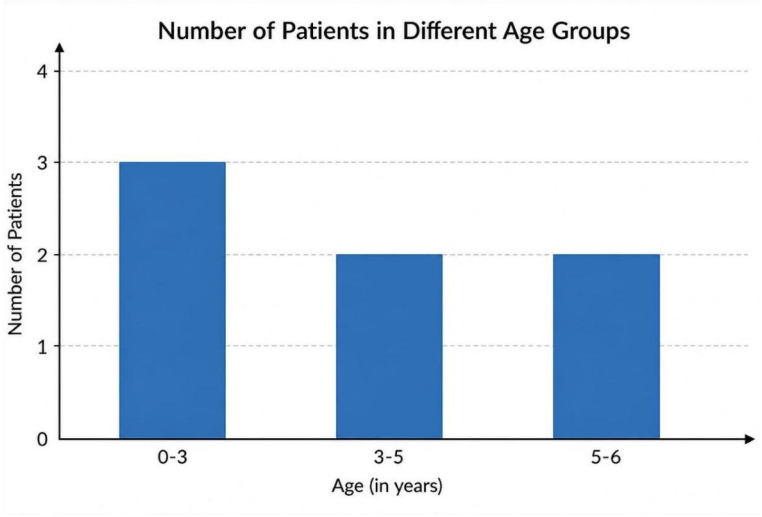

Fig.3.1

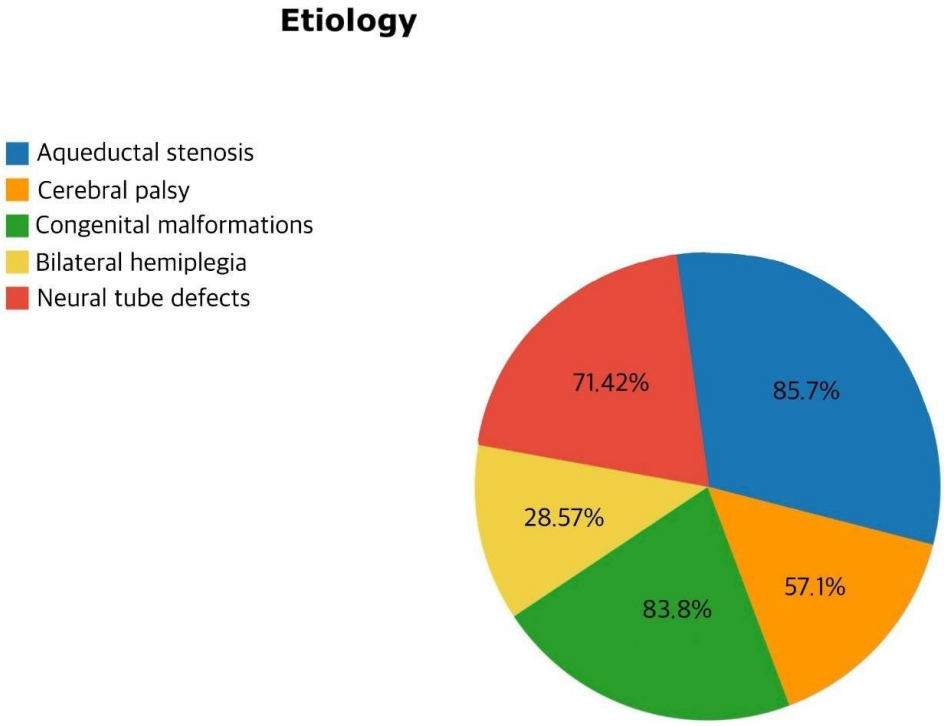

Fig.3.2.

Data Collection:

From the cases reviewed, information was gathered on age, year of diagnosis of pediatric hydrocephalus, presenting clinical features, laboratory findings, and therapeutic interventions. Diagnostic evaluations conducted within months before and after diagnosis were also documented,

including MSCT, MRI, and CT imaging. Data Base Used: Google scholar, Pub- Med, Pak Medinet, MSD manuals and EMRO who. In addition, certain details regarding the onset and progression of ventricular dilation, frequency of symptoms, prior history of head injury, congenital anomalies, intracranial tumors, and some cases with unidentified etiology were extracted from the available records.

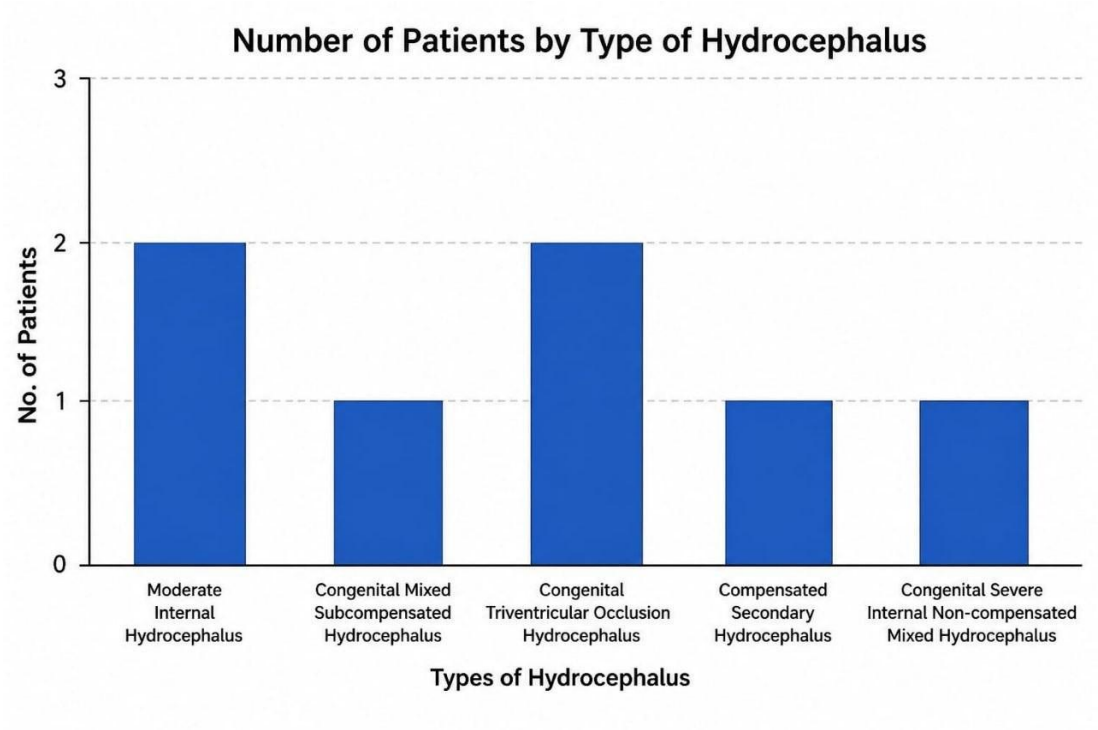

Fig.3.3.

The data analyzed in this study were exclusively from the cases associated with conditions such as cystic atrophic degeneration, encephalopathy, intracranial hypertension, cerebral palsy, expansion of perivascular spaces (Virchow -Robin spaces), and more white matter abnormalities amongst others relevant to hydrocephalus. In addition, conditions which coexisted were documented, including anemia, allergic disorders, hemiparesis, diabetes, rhinitis, and few other minor complications. Some cases were excluded from the analysis due to the clinical information being incomplete or lacking the diagnostic records.

Among these cases, some of the most frequently observed underlying causes included intracranial hypertension, cystic arachnoiditis, cerebral atrophy, leukodystrophy and encephalomalacia. A considerable portion of cases showed differing responses to medical management, with many lacking consistent documentation of treatment. With the recorded therapies, different medications were used, though, a significant number of patients had no reported treatment history, reflecting variability in management and incomplete clinical records.

Neuroimaging and EEG data:

Laboratory investigations were performed as according to medical requirement.

MRI, MSCT and CT, were utilized in majority of the cases (approximately 95%) to determine the causes and abnormalities associated with it.

MRI commonly demonstrates features such as encephalopathy, congenital stenosis, bilateral hemiparesis, cranioplasty, arachnoid cysts and internal hydrocephalus. [3] MSCT results reveal cystic degeneration, cystic scar forming in the temporal lobe, cystic cerebral arachnoiditis and subarachnoid space expansion. CT scan identifies conditions like dyscirculatory encephalopathy, changes in the left frontal lobe and multiple focal brain lesions.

Overall, the tools provided insights into the pathological and structural changes in the development of hydrocephalus, across the analysis.

The image show an MRI scan of aqueductal stenosis.

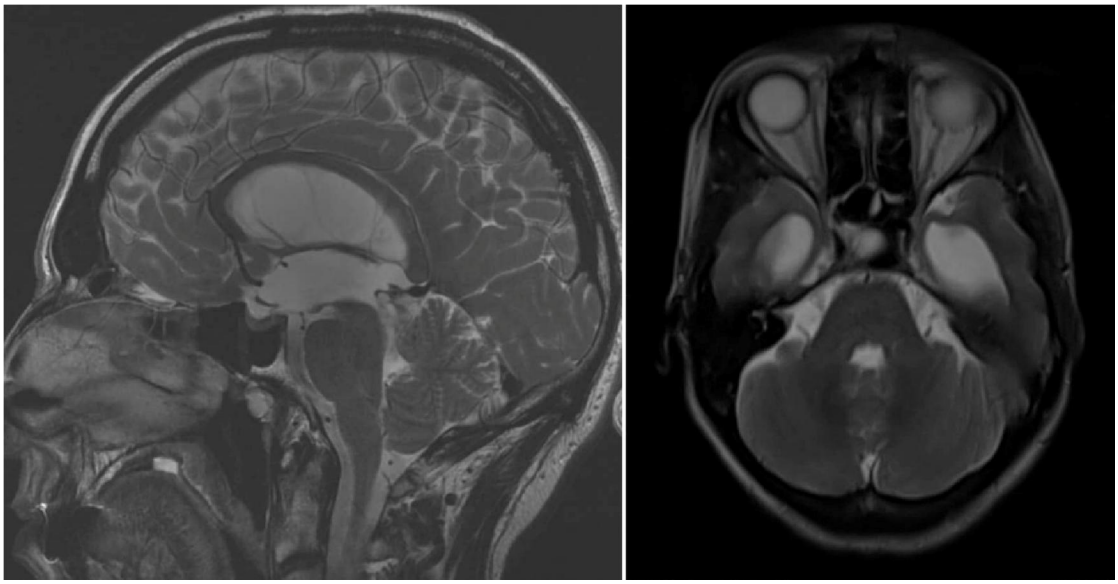

Fig.3.4.

Results

Study Population and Characteristics

A total of 7 pediatric patients (Patients A–G) aged 2 months to 6 years , all diagnosed with hydrocephalus . All information regarding these cases were collected from MRI, CT/MSCT, tractography, and neurosurgical consultation reports. All patients were children with earlyonset disease, with symptoms beginning since birth or early infancy. All cases shared a common feature of early disease manifestation, with onset occurring either since birth or during

early infancy. However, differences were observed in severity and underlying cause. Patients such as D, E, and F demonstrated more severe congenital or obstructive forms of hydrocephalus requiring or planned for surgical intervention, while A, B, and C showed relatively compensated or secondary forms

managed conservatively. Patient G represented a congenital sub compensated triventricular occlusion. The image depicts arachnoid cyst of posterior cranial fossa:

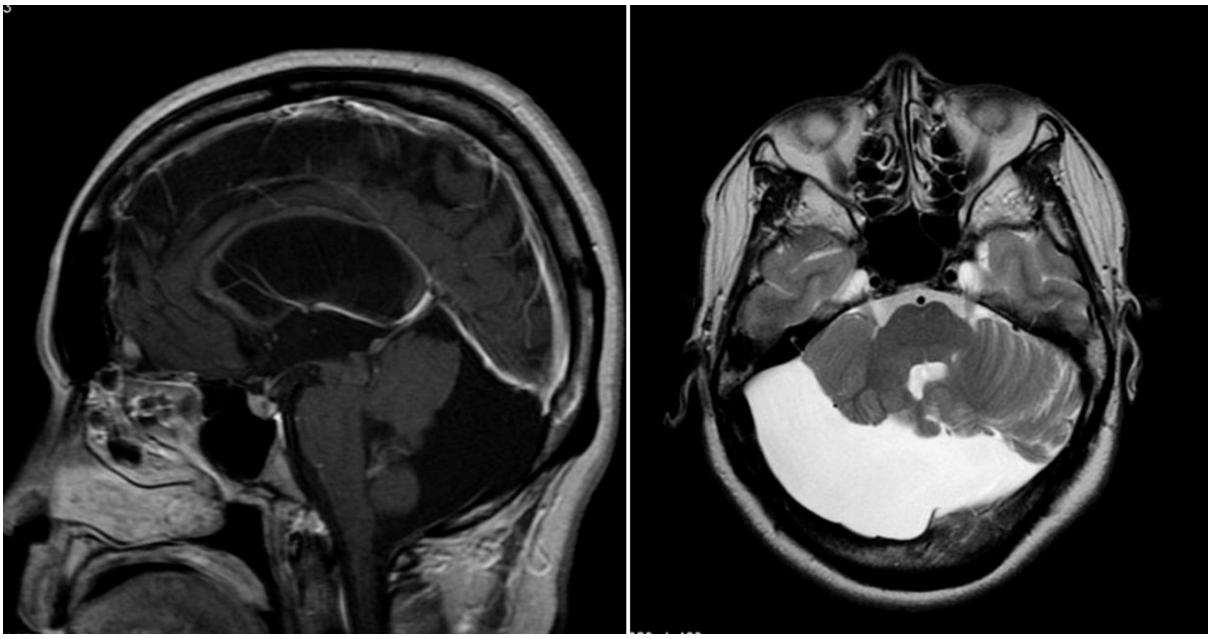

Fig 4.1

The majority of cases were associated with congenital or perinatal CNS pathology, including hypoxic-ischemic encephalopathy, aqueductal stenosis, and structural brain malformations, while a few showed secondary brain injury or metabolic causes. No tumor-related hydrocephalus was observed.

patient	age	hydrocephalus type	etiology	onset	trauma	treatment
A	Infant	Congenital mixed subcompensated hydrocephalus	Aqueductal stenosis and secondary CSF absorption failure	Birth	No	Conservative
B	Infant	Compensated secondary hydrocephalus	Hypoxic and ischemic encephalopathy	Birth	Maybe	Conservative
C	4 yrs	Sub compensated tri ventricular hydrocephalus	Aqueductal stenosis	Early childhood	Yes	Conservative
D	3 yrs	Congenital triventricular occlusive hydrocephalus	Cerebral palsy, aqueductal stenosis	Birth	No	Vp shunt planned
E	Infant	Internal occlusive triventricular hydrocephalus	Extensive cystic atrophy of cerebellar hemisphere and corpus callosum	Birth	No	Not yet
F	6 yrs	Severe internal non-compensated mixed hydrocephalus	Congenital and bilirubin encephalopathy	Birth	No	Vp shunt performed
G	5 yrs	Internal occlusive subcompensated triventricular hydrocephalus	Aqueductal stenosis, cerebral palsy, bilateral hemiplegia	Early childhood	No	Not specified

Fig.4.2.

Diagnostic Findings

In all 7 pediatric patients (A–G), MRI was performed (100%) and consistently demonstrated ventricular system enlargement and thinning of the corpus callosum consistent with hydrocephalus, making it the primary diagnostic feature across the cohort. The severity ranged from mild ventricular dilation to severe obstructive and mixed hydrocephalus.

Additional MRI findings varied between patients. Severe structural abnormalities, including white matter injury, encephalomalacia, corticospinal tract damage, and cystic brain changes, were mainly observed in patients B , E and F ,while patients A, C, and D showed relatively preserved brain parenchyma with mainly ventricular enlargement.. Patient E has dilated lateral ventricle due to aqueductal stenosis . Patient G demonstrated additional posterior fossa cystic abnormality contributing to CSF circulation disturbance. [4] Patient F and G has expansion in the left posterior cranial fossa and cerebromedullary cisterna due to cerebral arachnoiditis. Since 2 people out of 7 were identified with cerebral arachnoiditis involvement this represents approximately 28.6%of the cohort, highlighting its role as a contributing factor in CSF circulation abnormalities.

Surgical Evaluations

Among the 7 pediatric hydrocephalus patients (A–G), surgical management varied according to disease severity and type of hydrocephalus. Patients D and F underwent or were planned for ventriculoperitoneal (VP) shunt implantation, reflecting severe obstructive and mixed hydrocephalus requiring CSF diversion. Patient E, due to aqueductal stenosis and severe ventricular dilation, was also a strong surgical candidate, although intervention status was not documented.

Patients A, B, and C were managed conservatively without surgical intervention, as their hydrocephalus was compensated or secondary in nature. Patient G had a mixed hydrocephalus with posterior fossa cyst, but no confirmed surgical procedure was reported, suggesting further evaluation or individualized management.

Overall, approximately 2 out of 7 patients (F and D) had direct or planned surgical shunt procedures, while the remaining cases were either conservatively managed or under surgical consideration. The most common surgical approach in severe cases was VP shunt placement for CSF diversion, highlighting its role as the primary treatment modality in advanced pediatric hydrocephalus.

Discussion

In a series of 1000 babies every two infant is affected by hydrocephalus. It rules as one of the most common reasons for brain surgery in children since most emergency cases do not suffice with an effective treatment plan. The most common characteristic across the collection of cases was that ventriculomegaly or hydrocephalus is mostly congenital. Its causes could be trauma, during birth, genetic defect or premature birth.

Categorizing the cases has helped in distinguishing each of the hydrocephalus . Compensated secondary hydrocephalus is observed in 14.2% of our cases which is as a result of hypoxic and ischemic encephalopathy which was in turn due to a traumatic childbirth. As a result of hypoxia the patient

suffered decreased myelination degree and encephalomalacia of the left parietal and left occipital regions of the brain.

Sub compensated tri-ventricular hydrocephalus affected 28.57% cases of our study and this was as a result of aqueductal stenosis. Congenital mixed sub compensated hydrocephalus was observed in 14.2% of cases that was reviewed indicating aqueductal stenosis and secondary CSF absorption failure. Non compensated mixed hydrocephalus was seen in 14.2% of the cases which showed a subarachnoid space expansion in the MSCT scan. Ventroperitoneal shunt was inserted on this patient as a surgical approach.

A case of Subcompensated internal occlusive triventricular hydrocephalus stood out as it was one of the cases with a complete follow up in our study. The child was a premature baby and had cerebral palsy and bilateral hemiplegia. This just contributes more to them having aqueductal stenosis and therefore a subcompensated triventricular hydrocephalus. This patient underwent a ventroperitoneal shunt placement and endoscopic 3rd ventriculostomy.

About 2 out of 7 cases in our study had internal occlusive triventricular hydrocephalus but one among those cases showed aqueductal stenosis as a result of gliosis and the other showed aqueductal stenosis due to expansion of perivascular robin virchow spaces.[5] They had a ventroperitoneal shunt placed as treatment.

Several common symptoms were seen across the board such as psychomotor developmental delay, increased intracranial pressure and cerebral palsy which may act as a secondary cause to the respective cases of hydrocephalus. Associated symptoms of internal occlusive triventricular hydrocephalus include delayed development, muscle stiffness, seizures, poor co-ordination or balance and cognitive difficulties.

Conclusion

Pediatric hydrocephalus is one of the most common neurological disorder observed in children. This study was conducted to analyze the different types of hydrocephalus, their causes and treatment of approach. The conclusion we have reached is that most of these occur due to a condition know as aqueductal stenosis. The most common and acceptable surgical approach as of the current situation is CSF drainage using a ventroperitoneal shunt (VP shunt) and an Endoscopic 3rd ventriculostomy which is done by creating a small hole in the floor of the 3rd ventricle thereby allowing the passage of the Cerebrospinal fluid (CSF) and eliminating any block. A Study conducted by Mahmoud et al in Sudan found stenosis of aqueduct of Sylvius to be the most common cause (45%) followed by spina bifida (30%), Arnold Chiari malformation (20%) and Dandy Walker formation (5%).[6] These causes developmental delays and cannot be cured.

Early detection of Hydrocephalus and congenital anomalies can be detected through CT and Ultrasound scans. Though congenital complications can't be cured a planned approach for surgery can help the patients as they develop and grow.

We can therefore conclude that this study has accomplished it's aim of categorizing the different cases of Hydrocephalus with the information that was collected from the neurosurgery department of Samarkand State Medical University.

References

1. Congenital Hydrocephalus ByAi Sakonju, MD, SUNY Upstate Medical University
2. Reviewed ByAlicia R. Pekarsky, MD, State University of New York Upstate Medical
3. University, Upstate Golisano Children's
4. Hospitalhttps://www.msdmanuals.com/professional/pediatrics/congenital-neurologicanomalies/congenital-hydrocephalus#Etiology_v41359257
5. Complex hydrocephalus (combination of communicating and obstructive type): an important cause of failed endoscopic third ventriculostomy
6. Yad Ram Yadav 1,✉, Gaurav Mukerji 1,2, Vijay Parihar 1, Mallika Sinha 1, Sanjay Pandey
7. PMCID: PMC2717972 PMID:
8. 19604413https://pmc.ncbi.nlm.nih.gov/articles/PMC2717972/
9. Evaluation of hydrocephalus and other cerebrospinal fluid disorders with MRI: An update
10. Merve Gulbiz Kartal 1,✉, Oktay Algin 1
11. Cystic malformations of the posterior fossa: differential diagnosis clarified through embryologic analysis S S Kollias 1, W S Ball Jr, E C Prenger https://pubmed.ncbi.nlm.nih.gov/8031352/
12. Virchow-Robin Space Medicinehttps://www.sciencedirect.com/topics/veterinary-scienceand-veterinary-medicine/virchow-robin-space
13. Hydrocephalus and Its Diagnosis - A Review
14. Review Article -Ambren Surti, Ambreen
15. Usmahttps://applications.emro.who.int/imemrf/666/J-Bahria-Univ-Med-Dent-Coll-2020-10-
16. 1-72-76-eng.pdf?utm